



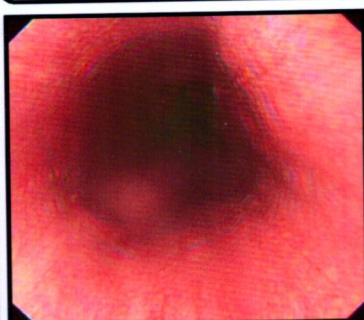
Endoscopy Report

تاریخ : ۱۴۰۱/۱۰/۰۳

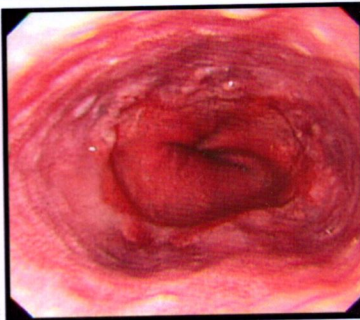
سن : ۵۷

نام بیمار : حسن اصغری

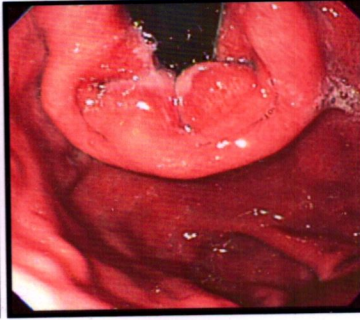
کد ملی : ۱۳۷۷۲۲۱۹۱۱



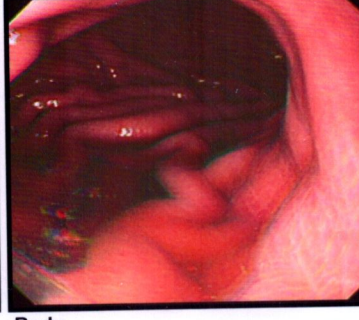Middle third



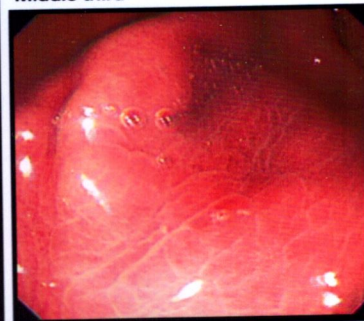
Lower third



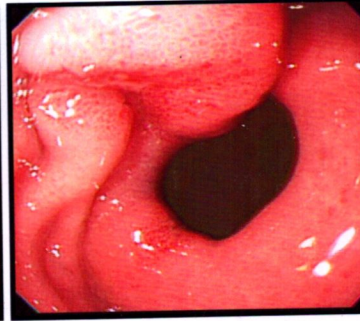
Cardia



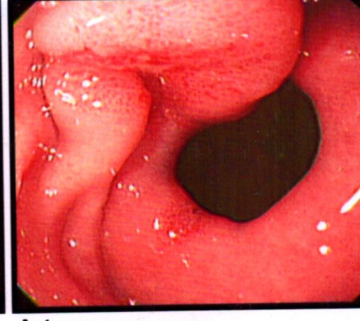
Body



Body



Antrum



Antrum

Reason for endoscopy : POSITIVE OB , دیسپسی مقاوم به درمان

Premedication : Midazolam

Esophagus : Grade A esophagitis was seen.

Stomach : Severe congestive erosive pangastritis with mosaic pattern in body and lesser curvature was seen. A 2*2 cm raised ulcer in prepylorus was seen. BXs were taken.

Duodenum : Bulb, D1 to D2 and 2nd part of the duodenum were normal

Diagnostic and therapeutic operations : GRADE A ESOPHAGITIS
SEVERE EROSIIVE GASTRITIS
GASTRIX ULCER

دکتر زین العابدین ابراهیم زاده

متخصص بیماری های داخلی
فوق تخصص بیماری های گوارش کبدومجازی صفراوی
نظام پزشکی ۵۹۱۱۲